

Ultrasound – Transabdominal & Transvaginal Pelvis Evaluation

PURPOSE:

To evaluate the uterus (myometrium and endometrium), adnexa (ovaries and fallopian tubes), and cul-de-sac in non-pregnant women.

SCOPE:

Applies to all ultrasound pelvis studies performed in Imaging Services / Radiology

ORDERABLE:

- EPIC Order: US Pelvis

CHARGEABLES:

- US Pelvis Transabdominal Limited (cpt 76857)
- US Pelvis Transvaginal (cpt 76830)
- *** US Doppler Complete (cpt 93975)

INDICATIONS:

- Signs (example: mass) or symptoms (examples: pain, bleeding) referred to the pelvis
- Localization of an intrauterine device (IUD)
- Abnormal lab values (decreased hemoglobin, increased CA-125, etc)
- Evaluation of endocrine abnormalities, including polycystic ovaries
- Post-partum complications, fever or pain
- Evaluation for primary neoplasm in setting of risk factors
- Evaluation of congenital uterine, gonadal, or lower genital tract abnormalities
- Follow up known pelvic abnormalities
- Abnormal pelvic findings on other imaging studies

CONTRAINDICATIONS:

- No absolute contraindications.
- For immediate postpartum patients (less than 6 weeks), OB/GYN should have been consulted and authorized a transvaginal exam.
- **Transvaginal approach should not be performed on an unemancipated minor without verbal consent from a parent/legal guardian, on a patient who is virginal, and/or has refused the exam.**
- If transvaginal imaging is not possible, use protocol “US Pelvis Transabdominal Complete”

EQUIPMENT:

Curvilinear transducer with a frequency of 2-9 MHz or greater that allows for appropriate penetration and resolution depending on patient's body habitus for transabdominal approach.

Endovaginal transducer with a frequency of 5 MHz or greater for transvaginal approach. Probe cover.

* - UTSW ER patients only

PATIENT PREPARATION:

- Review any prior imaging, making note of abnormalities requiring further evaluation.
- For transabdominal approach, bladder should be distended with urine
 - If the patient presents without a full bladder, we do NOT need to wait for bladder filling prior to starting the exam (eg. no need to stop exam and have patient drink).
 - **CAVEATE:** If the exam is TA only, or TV is unable to be performed (eg. patient pain, deferment, other technical challenges), then a full bladder is needed.
- For transvaginal approach:
 - Obtain verbal consent from patient or, if an unemancipated minor, from parent/guardian
 - Obtain chaperone (requirement for all male sonographers)
 - If postpartum (less than 6 weeks), ensure OB/GYN has authorized a transvaginal exam.
 - The bladder should be empty
- * For women of child-bearing potential presenting to the Emergency Department, a urine pregnancy test (UPT) or serum bHCG level MUST be obtained prior to exam initiation. If UPT is negative or bHCG is 0.0, then proceed with this exam.
 - A negative UPT must be from within the last 24 hours and documented in EPIC. A home UPT is not sufficient.
- In reproductive-aged postmenarchal patients, assessment of the endometrium requires knowledge of the phase of menstrual cycle and hormonal supplementation.
- **If UPT/bHCG is positive, then use protocol "US OB First Trimester."**

EXAMINATION:

GENERAL GUIDELINES:

- **A chaperone is required for male sonographers. Chaperone's name should be documented in Tech Notes and Electronic Health Record.**
- This exam focuses on transvaginal imaging, with the use of transabdominal imaging to review and confirm transvaginal findings or interrogate structures not visible by the transvaginal approach.
- A complete examination includes evaluation of the entire uterus (myometrium and endometrium), adnexa (ovaries and fallopian tubes), and cul-de-sac.

EXAM INITIATION:

- Introduce yourself to the patient.
- Verify patient identity using patient name and DOB.
- Explain test.
- **Obtain patient history including symptoms and last menstrual period (LMP).** Enter and store data page.
 - For women of child-bearing potential presenting to the Emergency Department, record urine pregnancy test (UPT) or bHCG results. For these exams, UPT should be negative / bHCG should be 0.0. **A negative UPT must be within the last 24 hours and documented in EPIC. A home UPT is insufficient.**
- Place patient in supine and/or lithotomy position.
- For transvaginal exam, apply endovaginal probe cover. For immediately post-partum patients, consider a sterile probe cover.

* - UTSW ER patients only

TECHNICAL CONSIDERATIONS:

- Always review any prior imaging, making note of abnormalities requiring further evaluation.
- Transabdominal approach used to evaluate structures that may not be completely evaluated transvaginally. Examples: Fundal fibroids; high-riding ovaries; large adnexal masses.
- Endovaginal transducer may be introduced by the patient, sonographer, or physician.
- Uterine length is measured on the long axis image from fundus to cervix (external os). In a flexed uterus, segmental measurements may be needed. AP dimension or depth of the uterus is measured on the same long axis view perpendicular to the length from anterior to posterior wall. Maximum width is measured on the transverse view.
- For anteverted/anteflexed uterus, endovaginal transducer should be placed in the anterior vaginal fornix. For retroverted uterus, the posterior fornix often improves visualization of uterus and endometrium (see Appendix).
- For a neutral position uterus, gentle abdominal pressure may help flex the uterus anterior or posterior to improve endometrial visualization.
- Evaluate myometrium and cervix for contour change, echogenicity, masses, and cysts. Note any discrepancy in thickness between the anterior and posterior myometrium.
- Measure the largest fibroid(s) with particular attention to any fibroids that contact the endometrium.
- Endometrial thickness is measured on the midline longitudinal image including anterior and posterior basal endometrium and excluding adjacent hypoechoic myometrium and endometrial fluid. It should be noted if the endometrium is not adequately seen in its entirety or is poorly defined; in this circumstance, the measurement should not be included in the report.
- Evaluate the endometrium for uniformity, focal abnormality, fluid/masses in the endometrial cavity, and presence/location of IUD.
- 3D acquisitions must be acquired for all patients presenting for evaluation of an IUD with coronal reformatted images submitted to PACS.
- Addition of reconstructed coronal view of the uterus from 3D acquisition may also be useful for evaluation of congenital uterine anomalies.
- Mullerian anomalies (eg. Unicornuate, bicornuate, didelphys, etc) are often associated with renal anomalies (eg. Agenesis), so images of each kidney are helpful with mullerian anomalies are suspected.
- Measure the ovaries in 3 dimensions on views obtained in 2 orthogonal planes. Ovaries may not be identifiable, usually prior to puberty, after menopause, or in the setting of large fibroids. Survey the adnexal region, cul-de-sac, and around the uterine fundus.
- An abnormal ovarian location, such as in the posterior cul-de-sac with adhesion, particularly to the uterus, pelvic side wall, or contralateral ovary, should be documented, as this may indicate endometriosis, other sources of adhesions, or displacement of the ovary in the setting of ovarian torsion.
- Survey the adnexal region for masses and dilated tubular structures. Normal fallopian tubes are not commonly identified. 3D acquisitions may also be helpful to differentiate ovarian multiseptated cysts from hydrosalpinx.
- Use of the “sliding sign” can help demonstrate the presence or absence of mobility of an adnexal structure in relation to the ovary. Sliding sign is also important for cervix/rectal mobility, and requires position of the probe in the posterior fornix.

* - UTSW ER patients only

- If the ovaries are not visualized, include image labeled “Adnexa” including the ipsilateral iliac vessels
- Evaluate cul-de-sac for presence of free fluid or mass. Differentiate mass from bowel loops.
- Special attention to the posterior cul-de-sac should be made in women with pelvic pain, fixed retroflexion of the uterus, or sonographic evidence of posterior adenomyosis and in those with known or clinically suspected endometriosis. Hypoechoic masses with tapering ends in the rectosigmoid wall may be seen in deeply infiltrating endometriosis. The presence of adhesions in the cul-de-sac may be inferred in the absence of a normal uterine sliding sign during dynamic imaging.
- Focal abnormalities should be documented with size measurements in 3 dimensions, color Doppler, and its relationship to adjacent structures.
- Note and report any tenderness during the exam.

* - UTSW ER patients only

DOCUMENTATION:

- **Transabdominal approach:**
 - **Used to evaluate structures that may not be completely evaluated transvaginally**
 - Examples: Fundal fibroids; high-riding ovaries; large adnexal masses.
 - Uterus
 - Longitudinal image of midline
 - Transverse images in mid uterus
 - Measurements in 3 orthogonal planes if uterus is not completely seen transvaginally (not needed if completely seen transvaginally)
 - NOTE: If area not well seen transvaginal (eg. Large fibroids), these areas/structures must be included in detail trans-abdominally
 - Ovaries
 - Longitudinal and transverse images of each ovary
 - or “Adnexa” if ovary is not visualized
 - Include in image the ipsilateral iliac vessels
 - Representative image without and with measurements in 3 orthogonal planes if ovary only seen transabdominally (not needed if seen transvaginally)
 - Other
 - Images without and with color Doppler of any large abnormalities that may be suboptimally visualized by transvaginal approach. Abnormalities may pertain to ovaries/adnexa, large uterine fibroids, or other pelvic masses
 - For any suspicion of mullerian anomaly (eg. Primary amenorrhea; unicornuate, bicornuate, didelphys uterus, etc), longitudinal image of each kidney is required.
- **Transvaginal approach:**
 - Uterus
 - Longitudinal images:
 - Cervix and cul-de-sac
 - Right of midline, midline, and left of midline
 - Midline with length and AP measurement
 - Midline with endometrial thickness measurement and color Doppler (annotate LMP if not stored on data page)
 - Transverse images:
 - Cervix and cul-de-sac
 - Lower uterine segment
 - Mid body with transverse measurement
 - Fundus
 - Color Doppler
 - Longitudinal of endometrium
 - Any focal endometrial or myometrial abnormalities
 - Cine sweep, transverse (superior to inferior) and longitudinal through uterus
 - 3D acquisition
 - For IUD evaluation, 3D images through the endometrial cavity must be obtained with coronal reformatted images submitted to PACS (on 3D-capable ultrasound devices only).

* - UTSW ER patients only

- 3D acquisitions for additional indications (examples: infertility; congenital anomalies).
- Ovaries, Right and Left
 - Longitudinal and transverse images through each ovary
 - or “adnexa” if ovary is not visualized
 - Include in image the ipsilateral iliac vessels
 - Representative images without and with measurements in 3 orthogonal dimensions, if well seen
 - Doppler
 - Representative color Doppler images
 - **Arterial and venous spectral Doppler waveforms if indication is pain, or suspicion for torsion**
 - Cine sweep, transverse (superior to inferior) and longitudinal of each ovary
- Cul-de-sac
 - If not included above.
- Other
 - Sliding sign
 - For indication that may include endometriosis
 - If there is no mobility of the uterus/cervix against the rectum, perform dedicated sweeps out laterally and transverse from the posterior fornix.
 - Abdominal Compression for Ovarian mobility
 - Holding the TV probe stationary with the ovary in view, use the other hand to compress the abdomen directly over the ovary to evaluate for ovarian mobility next to the UT, the 2nd ovary, adnexal mass, and/or bowel
 - Performed when there are concerns for ovarian adhesions.
- Data page(s)

PROCESSING:

- Review examination images and data
- Export all images to PACS
- UTSW: Confirm data in Imorgon (where applicable)
- Document relevant history (including UPT results or bHCG level, if applicable *) and any study limitations.

* - UTSW ER patients only

REFERENCES:

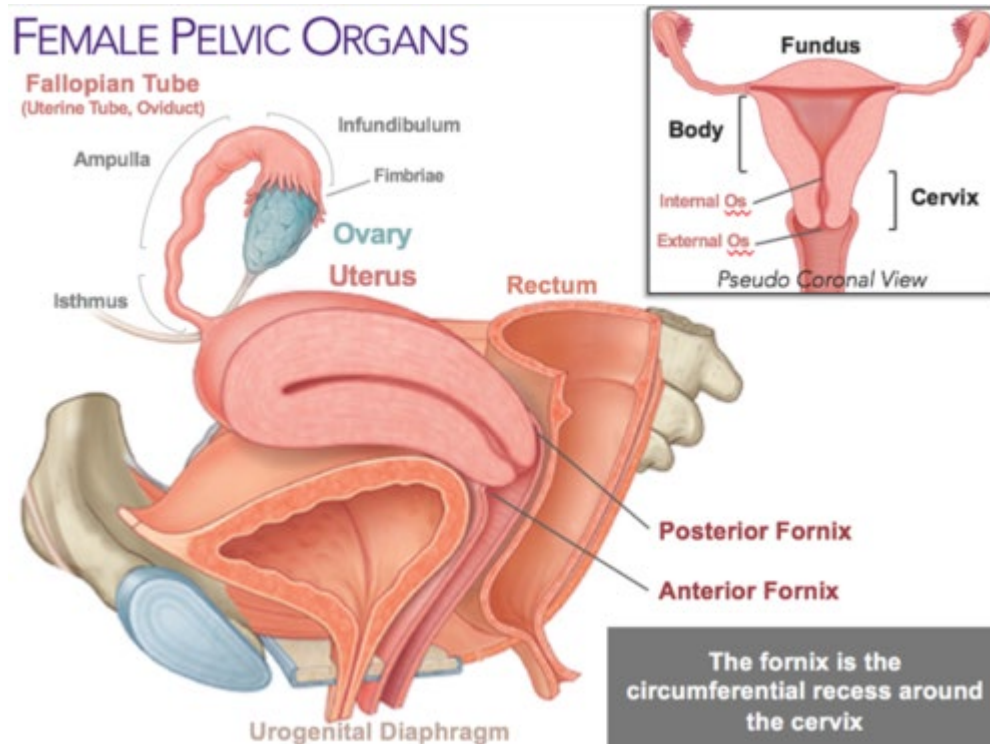
ACR-ACOG-AIUM-SPR-SRU Practice Guideline (2020 Update)

REVISION HISTORY:

SUBMITTED BY:	David T. Fetzer, MD	Title	Medical Director
APPROVED BY:	David T. Fetzer, MD	Title	Medical Director
APPROVAL DATE:	11-09-2015		
REVIEW DATE(S):	10-30-2018		Theresa Huang, MD
REVISION DATE(S):	11-25-2015	Brief Summary	Added need to obtain UPT or bHCG prior to exam
	08-15-2016	Brief Summary	Clarified use of this protocol vs Transabdominal Complete whether TV is contra-indicated
	09-05-2016	Brief Summary	Added EPIC orderables
	03-10-2019	Brief Summary	Added Appendix with information regarding RPOC
	5-4-2019		Updated details regarding when, when not to obtain UPT/bHCG
	05-31-2020		Updates based on 2020 AIUM Practice Parameters; removed images to reduce redundancy, improve efficiency
	11/22/2022		For suspected mullerian anomalies, single image of each kidney is required. Additional information regarding use of posterior fornix.
	2/24/23		Added ovarian Doppler charge info and indication/justification for when to answer "YES" to Doppler end exam questions
	02/14/2024		Added documentation of "sliding sign" for indication of endometriosis
	12/26/2024		Added ovarian compression in "Documentation" section under "Other". Added clarification about bladder filling when TV exam is performable.

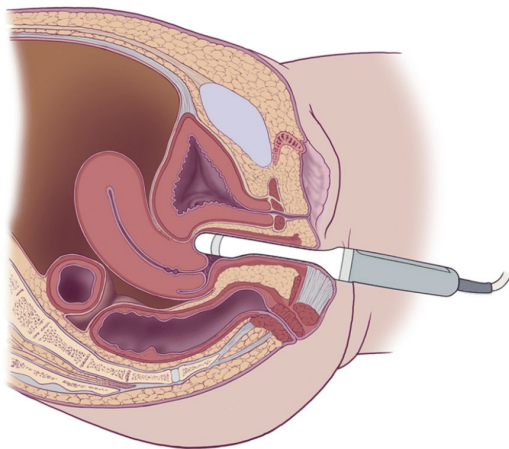
* - UTSW ER patients only

APPENDIX:

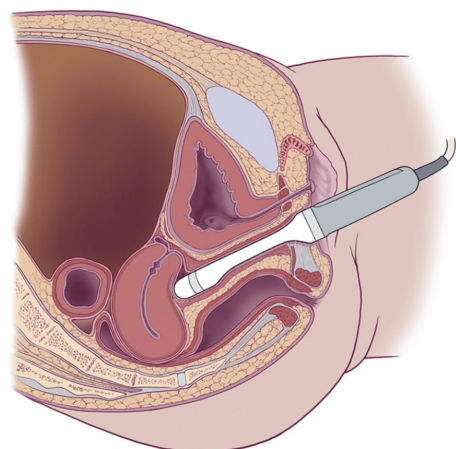


Anterior versus posterior vaginal fornix for optimal visualization of uterus

Anterior fornix – Best for anteverted/anteflexed uterus



Posterior fornix – Best for retroverted/retroflexed uterus



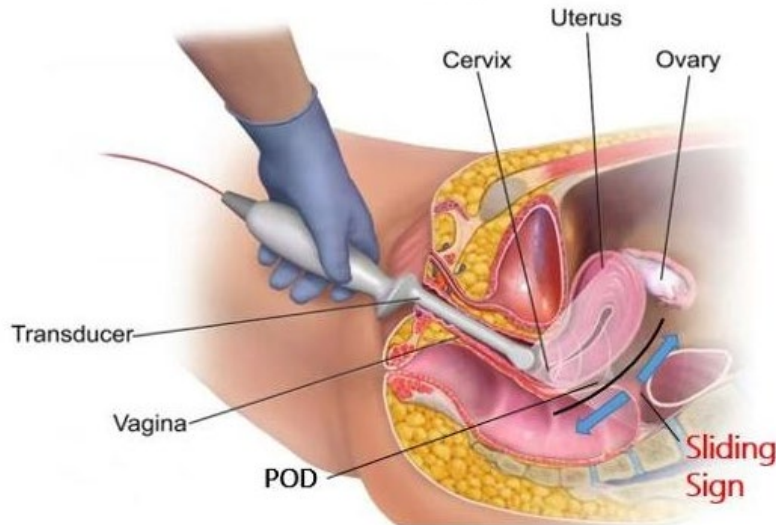
Sliding Sign:

[UOG video abstract: Prevalence of negative sliding sign representing pouch of Douglas obliteration during pelvic transvaginal ultrasound for any indication \(isuog.org\)](https://www.isuog.org/)

* - UTSW ER patients only

Aiming at the cervix or toward the posterior fornix, “scoop” the cervix down and up (blue arrow in diagram below). Visualize sliding of uterine body against anterior rectum (black line in diagram below).

Transvaginal ultrasound – the importance of the ‘sliding sign’



Testing for the ‘sliding sign’ should be an important integral part of any transvaginal ultrasound in someone with suspected endo. It tests whether the uterus and bowel slide freely against each other as they should. This is a positive sliding sign. If they do not move freely this is a negative sliding sign and is an indicator for obliteration of the POD (cul de sac) which is deep rectovaginal endo requiring referral to a specialist endo centre.

<https://healthunlocked.com/endometriosis-uk/>

Retained products of conceptions (RPOC):

- Exceedingly rare. May be more common in patients who have had elective or spontaneous abortions, who continue to have bleeding, though still rare.
- RPOC difficult on sonogram given similar appearance to blood clot, regardless of Doppler flow.
- A normal endometrial stripe/cavity is useful to exclude RPOC. Otherwise, diagnosis of RPOC is made based on clinical history/symptoms and presence of material in the endometrial cavity.
- bHCG levels are variable (even <2). Persistently elevated bHCG is more indicative of gestational trophoblastic disease.

Spectrum of US exam interpretation:

- Normal endometrium = no RPOC
- Heterogeneous endometrium/cavity without Doppler flow = likely blood/clot. RPOC cannot be entirely excluded.
- Focal heterogeneous hyperechoic endometrium with increased Doppler flow = suspect RPOC

* - UTSW ER patients only